

Posterior Capsular Contracture of the Shoulder

H. Gregory Bach, MD
Benjamin A. Goldberg, MD

Abstract

Posterior capsular contracture is a common cause of shoulder pain in which the patient presents with **restricted internal rotation** and reproduction of pain. Increased anterosuperior translation of the humeral head occurs with forward flexion and can mimic the pain reported with impingement syndrome; however, the patient with **impingement syndrome** presents with **normal range of motion**. Initial management of posterior capsular contracture should be nonsurgical, emphasizing range-of-motion stretching with the goal of restoring normal motion. For patients who fail nonsurgical management, arthroscopic posterior capsule release can result in improved motion and pain relief. In the throwing athlete, repetitive forces on the **posteroinferior capsule** may cause posteroinferior capsular hypertrophy and limited internal rotation. This may be the initial pathologic event in the so-called dead arm syndrome, leading to a superior labrum anteroposterior lesion and, possibly, rotator cuff tear. Management involves regaining internal rotation such that the loss of internal rotation is not greater than the increase in external rotation. In the athlete who fails nonsurgical management, a selective posteroinferior capsulotomy can improve motion, reduce pain, and prevent further shoulder injury.

Classic impingement in the shoulder involves pain on forward flexion that is localized over the supraspinatus insertion on the greater tuberosity.¹⁻⁴ Although associated loss of internal rotation has been described, the pain may be indicative of a posterior capsular contracture; loss of motion is not common with impingement.² The original description of impingement syndrome did not mention a capsular contracture limiting motion. Additionally, the morphology of the coracoacromial arch does not restrict internal rotation of the shoulder. Thus, in **impingement syndrome**, there should be **normal shoulder motion**.⁵ Although both

impingement syndrome and posterior capsular contracture may present with **pain on forward elevation**, only in the presence of posterior capsular contracture would the patient be expected to present with objectively decreased internal rotation.⁶

In a cadaveric study, posterior capsular contracture was shown to alter normal glenohumeral kinematics, resulting in **increased anterosuperior translation** of the humeral head **during shoulder flexion**.⁷ This can cause a form of nonoutlet impingement as the humeral head translates toward the coracoacromial arch^{8,9} (Figure 1). Harryman et al⁷ demonstrated that in vitro posterior capsular shortening results in limit-

Increased: Augment
Narrower: Anterior
Throwing: Laceration
Decreased:

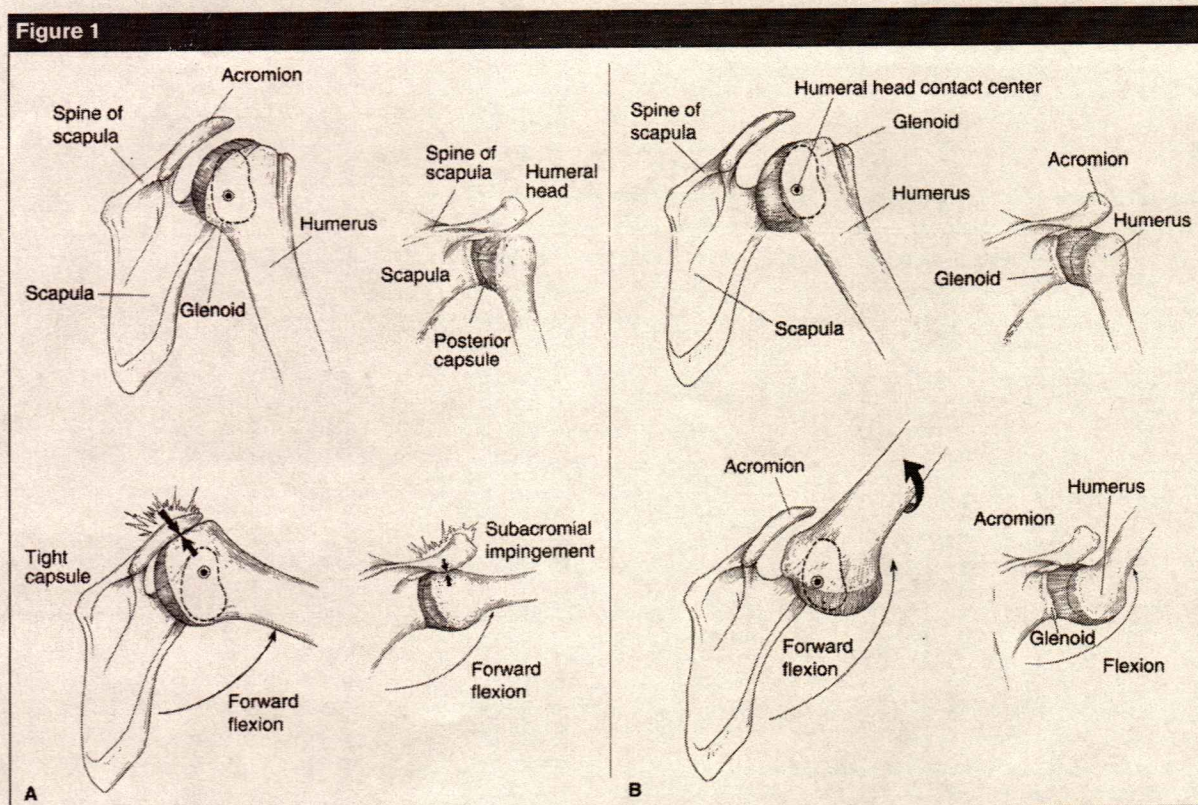
Dr. Bach is Resident, Department of Orthopaedic Surgery, University of Illinois—Chicago, Chicago, IL. Dr. Goldberg is Assistant Professor, Department of Orthopaedic Surgery, University of Illinois—Chicago, and Senior Attending Surgeon, Division of Orthopaedic Surgery, Cook County Hospital, Chicago.

None of the following authors or the departments with which they are affiliated has received anything of value from or owns stock in a commercial company or institution related directly or indirectly to the subject of this article: Dr. Bach and Dr. Goldberg.

Reprint requests: Dr. Goldberg, Department of Orthopaedic Surgery, University of Illinois—Chicago, 835 S Wolcott Avenue, M/C 844, Chicago, IL 60612.

J Am Acad Orthop Surg 2006;14:265-277

Copyright 2006 by the American Academy of Orthopaedic Surgeons.



A, A shortened posterior capsule causing obligate anterosuperior translation of the humeral head during forward flexion, resulting in nonoutlet impingement (inset images). Top, Normal resting arm position. Bottom, Posterior capsule contracture. **B**, When the capsule is of normal length (top and bottom), the humeral head remains centered on the glenoid during forward elevation and subacromial impingement does not occur (inset images). (Adapted with permission from Ticker JB, Beim GM, Warner JJP: Recognition and treatment of refractory posterior capsular contracture of the shoulder. *Arthroscopy* 2000;16:27-34.)

ed internal rotation and flexion.

Although adhesive capsulitis (ie, frozen shoulder) may present with limited internal rotation, it is considered to be a separate and different condition.⁹⁻¹⁴ Patients with adhesive capsulitis frequently have pain with shoulder flexion as well as complaints that resemble those of impingement symptoms; however, restricted range of motion (ROM) in all planes is usually present.

There are **three basic types** of posterior capsular contracture: (1) **idiopathic**, with the patient unable to remember any prior trauma; (2) **posttraumatic**, typically after a low-energy event, which may be misdiagnosed as a muscle strain; and (3)

postoperative, such as after a posterior capsular shift for posterior instability. However, procedures performed to manage a variety of shoulder conditions, including classic impingement, may result in posterior capsular contracture. In our experience, **idiopathic and posttraumatic** contractures typically **do well with nonsurgical treatment**; postoperative contracture often requires surgical release of the posterior capsule to restore motion and improve pain.⁸

Posterior capsular contracture also may occur in the **overhead throwing athlete**, especially in baseball pitchers.^{15,16} In these athletes, however, the contracture involves

the posteroinferior aspect of the capsule.^{15,16} Posteroinferior contracture most likely occurs in response to the stress loads associated with the follow-through motion in throwing.¹⁶ After ball release, the arm moves ahead of the body and exerts a large distraction force of approximately 750 N (approximately 80% of the pitcher's weight),¹⁷ which acts on the posteroinferior capsule.¹⁶ Because the shoulder is internally rotated in follow-through, the inferior part of the posterior capsule is rotated into a more posterocentral position, where it more directly resists the distraction force of follow-through.¹⁶ The reactive force of the shoulder musculature produces a

Although:
 - idiopathic
 - post trauma
 - post op (bicep post)
 - Athlete Arthroscopic

compressive load to resist this distraction force. The shoulder capsule is then subjected to repetitive high loads that cannot be completely resisted by muscle forces.¹⁶ This repetitive tensile loading of the posterior capsule could cause the **capsular hypertrophy** that is so common in the throwing athlete.¹⁶

Anatomy

The shoulder is a synovial joint with a capsule comprising four supporting layers: (1) the deltoid and pectoralis major muscles, (2) the clavicular fascia and conjoined tendon (short head of the biceps and coracobrachialis), (3) the deep layer of the subdeltoid bursa and rotator cuff muscles, and (4) the glenohumeral joint capsule and coracohumeral ligament.¹⁸ The shoulder capsule contains an extracellular matrix that is composed primarily of type I collagen, with lesser amounts of types II and III.¹⁹ The highly ordered crystalline arrangement of collagen in the extended conformation provides an anatomic structural basis for its viscoelastic properties.¹⁹

The posterior capsule originates from the posterior capsulolabral complex and extends from the posterior origin of the biceps tendon to the inferior aspect of the glenoid.¹⁹ At the inferior aspect of the shoulder joint is the inferior glenohumeral ligament (IGHL) complex.²⁰ This complex is bounded by an anterior band and a posterior band that perform like a hammock to support the humeral head with the arm in abduction.²⁰ The **posterior capsule**, which blends with the tendinous portion of the posterior aspect of the rotator cuff, **limits posterior translation** when the arm is **forward flexed, adducted, and internally rotated**.¹⁹ Additionally, the posterior capsule becomes taut in various positions of flexion and internal rotation and can limit excessive flexion and internal rotation.⁷

*Tightening = less range
blend: mélange*

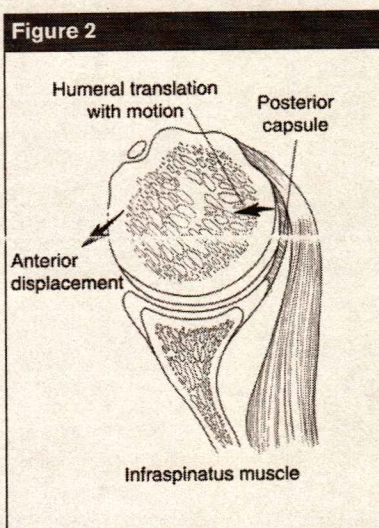


Figure 2
Effect of asymmetric tightening of the shoulder capsule. Rotating the humeral head produces tension in the tissues of a surgically tightened capsule, causing translation in a direction opposite to the tight-tissue constraint. This constraint opposes loads and displacement that are directed toward itself and acts to translate the humeral head on the glenoid in a direction away from itself. This mechanism of translatory motion is referred to as the capsular constraint mechanism. (Adapted with permission from Harryman DT II, Sidles JA, Clark JM, McQuade KJ, Gibb TD, Matsen FA III: Translation of the humeral head on the glenoid with passive glenohumeral motion. *J Bone Joint Surg Am* 1990;72:1334-1343.)

Pathoanatomy

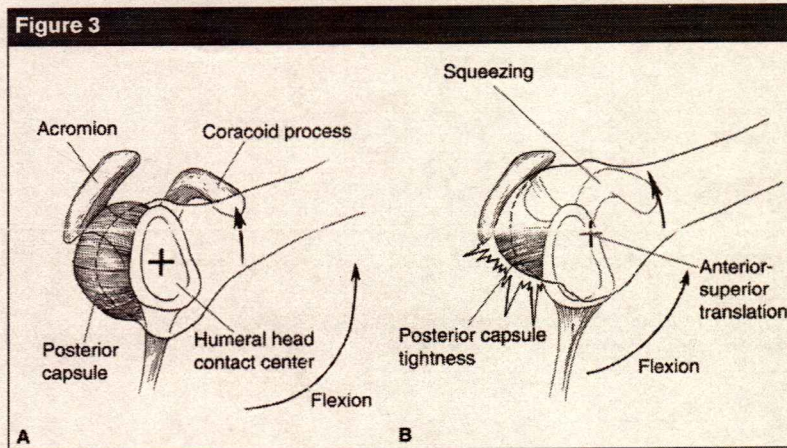
With experimental **tightening** of the shoulder capsule, there is **abnormal translation** of the **humeral head during glenohumeral rotation**.^{7,19} The translation occurs in the opposite direction of the capsular tightening.⁷ This mechanism of translational motion is referred to as the capsular constraint mechanism⁷ (Figure 2). Injury to this mechanism may lead to instability, articular damage, and symptoms of impingement.¹⁹ The impingement symptoms occur

through nonoutlet mechanisms; they are not related to the acromial morphology.^{9,19}

Harryman et al⁷ experimentally shortened the posterior portion of the shoulder capsule in seven cadaveric specimens. They confirmed that **tightening** of the **posterior capsule** results in **limited internal rotation**, **cross-body movement**, and **flexion** of the shoulder.⁷ Additionally, the authors demonstrated that posterior capsule tightening caused a significant increase in anterior translation of the center of the humeral head during both shoulder flexion ($P < 0.01$; from a mean of 3.79 to 7.27 mm) and cross-body movement ($P < 0.01$; from a mean of -0.14 to 6.63 mm).⁷ This anterior translation occurred earlier in the arc of motion in the study specimens than it did in a shoulder with a posterior capsule of normal length.⁷ Tightening of the posterior capsule also resulted in significant superior translation of the humeral head with flexion ($P < 0.05$; from a mean of 0.35 to 2.13 mm). As a result, the convex humeral head and bursal side of the rotator cuff are forced against the undersurface of the concave coracoacromial arch, which may cause compression of the cuff because the humeral head cannot remain centered in the glenoid² (Figure 3).

Gerber et al²¹ reported that posterior capsular plication significantly limits internal rotation. The authors performed a posterior capsulorrhaphy by surgically plicating one half the circumference of the capsule from the 6 o'clock to the 12 o'clock position. At 0° of abduction, posterior capsulorrhaphy limited internal rotation by 21.5°, or 48.2% of internal rotation ($P < 0.00001$).²¹ At 45° of abduction, posterior plication limited internal rotation by 27.2°, or 69.7% of internal rotation ($P < 0.0007$).²¹ At 90° of abduction, posterior capsulorrhaphy limited internal rotation by 21°, or 68.2% of internal rotation ($P < 0.0022$).²¹

*L64: diffuse tkt humeral
L64: impingement*



A, Normal capsular laxity allows the humeral head to remain centered during elevation. **B**, Tightness of the posterior capsule may create obligate anterosuperior translation with shoulder flexion. (Adapted with permission from Matsen FA III, Lippitt SB, Sidles JA, Harryman DT II: *Practical Evaluation and Management of the Shoulder*. Philadelphia, PA: WB Saunders, 1994, p 40.)

Posterior Capsular Contracture in the Overhead Throwing Athlete

In the overhead throwing athlete, the posteroinferior capsule may develop a contracture that causes a loss of internal rotation.^{15,16} Glenohumeral internal rotation deficit (GIRD) is the loss in degree of glenohumeral internal rotation of the throwing shoulder compared with the nonthrowing shoulder.^{15,16} The first recognition of the relationship of GIRD with shoulder dysfunction in the throwing athlete was in 1991.¹⁶ In this study, 39 professional baseball pitchers identified at spring training as having $\leq 25^\circ$ of total internal rotation (GIRD), with loss of internal rotation $\geq 35^\circ$, were followed for a single season.¹⁶ Sixty percent of these pitchers developed shoulder problems requiring them to stop pitching during the study period.¹⁶

Similarly, in a series of 38 arthroscopically proven symptomatic type II superior labrum anterior-posterior (SLAP) lesions in overhead athletes, significant GIRD was found in all affected shoulders (average, 33° ; range

of loss of internal rotation, 26° to 58°).¹⁶ In another study, high-level tennis players were followed prospectively for 2 years. One group performed daily posterior inferior capsular stretching to minimize GIRD, whereas the control group did not stretch.¹⁶ Over the 2-year study period, those who stretched increased internal rotation and total rotation compared with the control group; additionally, the stretching group had a 38% decrease in the incidence of shoulder problems.¹⁶ Finally, among 22 major league pitchers who were manually stretched daily during the 1997, 1998, and 1999 professional baseball seasons, there were reportedly no innings lost, no intra-articular shoulder pathology, and no surgical procedures.¹⁶

Posteroinferior capsular contracture in the overhead throwing athlete results in translation of the humeral head on the glenoid.^{15,16} A recent study investigated the amount of translation both before and after posteroinferior capsular plication in cadaveric shoulders tracked with electromagnetic sensors.¹⁶ The authors documented a posterosuperior shift of the humeral

head on the glenoid face of approximately 4.4 mm following posteroinferior capsular plication.¹⁶

Mechanically, the IGHL complex may be represented by two dominant structural components that function as interdependent cables—the anterior band and the posterior band.¹⁶ These primary passive constraints of the glenohumeral joint develop tension reciprocally and equally as the shoulder internally and externally rotates in the 90° abducted position.¹⁶ This defines the allowable envelope of motion of the shoulder, in much the same way that the four-bar linkage model defines allowable knee motion based on cruciate restraints.¹⁶

With external rotation of the humerus about its central contact point on the glenoid, the cables tighten and develop tension equally as they assume an oblique course across their allowable envelope of motion¹⁶ (Figure 4, A). When the posterior cable is shortened, as in posteroinferior capsule contracture, it acts as a tether, shifting the glenohumeral contact point posterosuperiorly during combined abduction and external rotation because the shortened posterior cable reaches its maximum elongation before the anterior cable maximally elongates.¹⁶ The anterior band continues to allow external rotation anteriorly, resulting in posterosuperior translation on the humeral head¹⁶ (Figure 4, B). With the posterosuperior shift of the arc of motion of the greater tuberosity, it ceases to abut the usual segment of the posterosuperior glenoid in combined abduction and external rotation, allowing additional external rotation to be obtained.¹⁶

The peel-back mechanism is a dynamic phenomenon that has been observed arthroscopically in overhead throwers with SLAP lesions.^{16,22} The peel-back, which occurs with the arm in the cocked position of abduction and external rotation, is caused by the force effect of the biceps tendon as its vector shifts to a

tether: attach

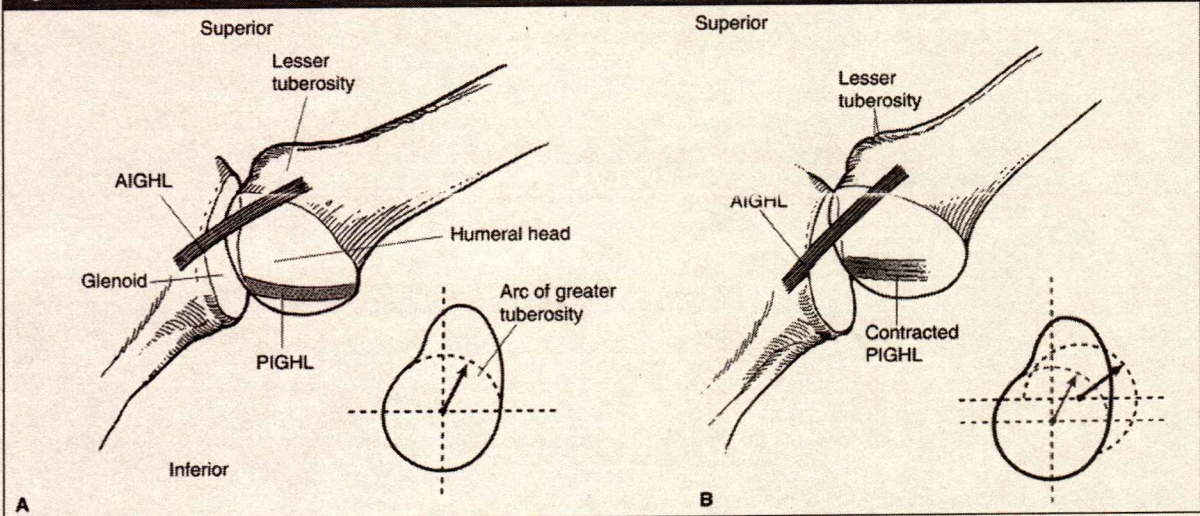
peel

pitcher: lanceus
whereas: fovea's qe

reportedly = Apparement.
shift: Kulelay

Cocked position: Anue

Figure 4



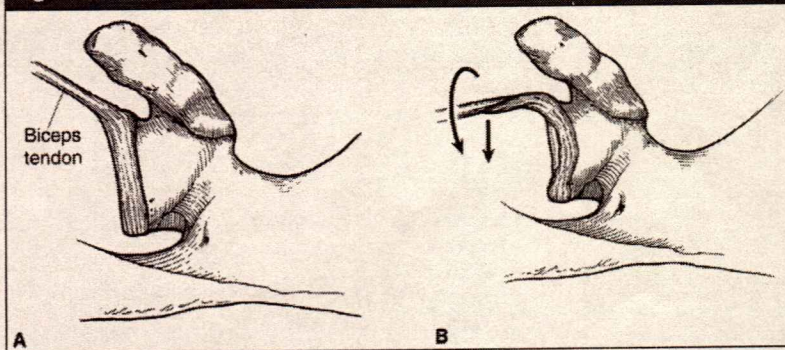
A, With abduction and external rotation, the two inferior glenohumeral ligament cables, set obliquely across the shoulder, reciprocally and equally develop tension. Inset, The greater tuberosity of the humerus has a well-defined circular arc (dotted line) before it contacts the posterior glenoid. **B**, When the posterior cable (PIGHL) shortens (contracted posterior band), the glenohumeral contact point shifts posterosuperiorly, and (inset) the allowable arc of external rotation (before the greater tuberosity contacts the posterior glenoid) increases significantly (dotted lines). AIGHL = anterior inferior glenohumeral ligament, PIGHL = posterior inferior glenohumeral ligament (Adapted with permission from Burkhart SS, Morgan CD, Kibler WB: The disabled throwing shoulder: Spectrum of pathology. I: Pathoanatomy and biomechanics. *Arthroscopy* 2003;19:404-420.)

more posterior position in late cocking.^{16,22} During arthroscopy, the biceps tendon can be seen to assume a more vertical and posterior angle, which produces a posterior shift in

the biceps force vector as well as a twist at the base of the biceps tendon, transmitting a torsional force to the posterior superior labrum^{16,22} (Figure 5). When the superior labrum

is not well-anchored to the glenoid, this posteriorly directed torsional force causes the humeral head and superior labrum to rotate medially over the corner of the glenoid onto the posterosuperior scapular neck.^{16,22}

Figure 5



Superior view of the biceps and labral complex of the left shoulder in the resting position (**A**) and in the abducted, externally rotated position (**B**) demonstrating the peel-back mechanism as the biceps vector shifts posteriorly (arrows). (Adapted with permission from Burkhart SS, Morgan CD, Kibler WB: The disabled throwing shoulder: Spectrum of pathology. I: Pathoanatomy and biomechanics. *Arthroscopy* 2003;19:404-420.)

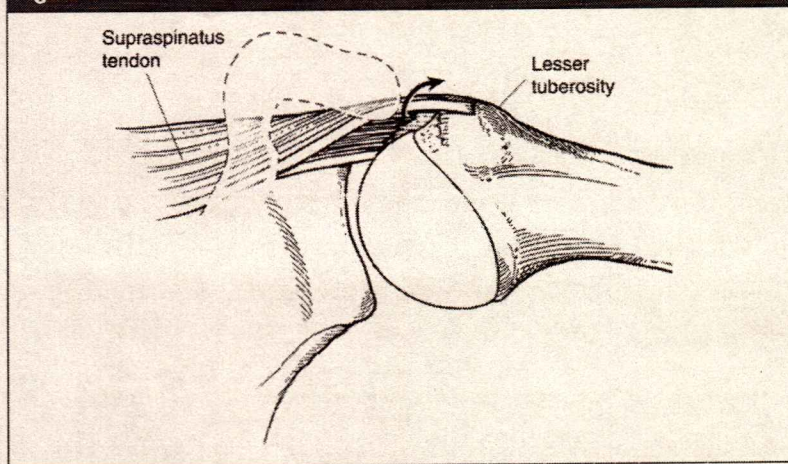
Acquired posteroinferior capsular contracture is the primary pathology that initiates a pathologic cascade, climaxing in the late-cocking phase of throwing.¹⁶ At that point, the shift in the glenohumeral contact point causes maximal shear stress on the posterosuperior labrum at exactly the time when the peel-back mechanism produces its maximum torsional effect on the posterosuperior labrum, putting the shoulder in a vulnerable situation.^{16,23} The increased shear forces at the biceps tendon insertion and the posterosuperior labral attachment cause both structures to begin to fail at their attachments, producing a posterior SLAP lesion.¹⁶ The SLAP lesion

As well as: anti-biomech.

Resting: Repos.

Shear: aiplement.

Figure 6



Torsional overload with repetitive twisting of rotator cuff fibers occurring at the articular surface of the rotator cuff, the most common location of cuff failure in the throwing athlete. (Adapted with permission from Burkhart SS, Morgan CD, Kibler WB: The disabled throwing shoulder: Spectrum of pathology. I: Pathoanatomy and biomechanics. *Arthroscopy* 2003;19:404-420.)

magnifies the shift and instability problem and can lead to the dead arm syndrome.¹⁵

Damage to the rotator cuff also may contribute to problems in the throwing shoulder. The increased external rotation of the shoulder may cause abrasion and tearing of the rotator cuff against the posterosuperior glenoid, resulting in damage to the cuff.¹⁶ An even greater adverse effect of excessive external rotation on the rotator cuff is that it allows repetitive twisting of the rotator cuff fibers, which can lead to torsional overload and shear failure of the cuff fibers. With the arm in the abducted, externally rotated position, the greatest shear stresses in the cuff will be at their attachment on the articular side, the location of cuff failure in the throwing athlete¹⁶ (Figure 6).

Evaluation

Clinical Assessment

With posterior capsular contracture, the shoulder is limited in its range of internal rotation in abduction, cross-body adduction, internal rotation up

the back, and flexion.² Symptoms include pain and difficulty with sleeping as well as in reaching both across the body and up the back (eg, to fasten a brassiere).² ROM measurements during physical examination may confirm the diagnosis of posterior capsular contracture by identifying loss of internal rotation, cross-body adduction, and, to a lesser extent, forward flexion while maintaining external rotation. Both active and passive ROM must be measured because pain may limit the patient's ability to actively maximally rotate the shoulder internally to the physical limits of ROM.

The physician will notice that passive internal rotation is asymmetric compared with the normal side. Internal rotation in 90° of abduction is assessed with the patient supine, and side-to-side differences are noted. The physician should examine the seated patient for internal rotation (the distance to the most cephalad spinous process to which the patient can apply the thumb).²⁴ There is usually asymmetry in motion compared with the contralateral

side, assuming the latter is without pathology.

Harryman et al⁷ advocated measuring adduction in the horizontal plane in the sitting or standing patient because these positions minimize any effect of chest or body rotation.⁷ This measurement is accurate assuming that the sides have similar scapulothoracic motion and humeral lengths. Maximal cross-body adduction is the minimal distance from the antecubital fossa to the contralateral acromion when the arm is adducted horizontally across the body²⁵ (Figure 7). This is repeated for the contralateral shoulder, and the measurements are compared.

External rotation of the shoulder in adduction (0° of abduction) and in 90° of abduction is expected to be nearly symmetric compared with the contralateral side. Posterior capsular contracture should be differentiated from adhesive capsulitis, which usually presents with global loss of motion. Thus, patients with adhesive capsulitis would be expected to have significantly diminished external rotation and, usually, more pronounced loss of flexion of the shoulder than is encountered in patients with posterior capsular contracture.

The Neer impingement sign is elicited by the examiner's elevating the shoulder with one hand while preventing scapular rotation.³ Neer thought that this maneuver caused the greater tuberosity to impinge against the acromion, thus producing pain in patients with impingement.³ However, shoulder flexion frequently causes pain in many other shoulder conditions; therefore, anterior impingement pain must be considered nonspecific. The Neer impingement test is positive when pain with shoulder flexion is eliminated after injection of 10 mL of 1.0% lidocaine into the subacromial space beneath the anterior acromion.³

The Hawkins impingement sign is positive when shoulder flexion to 90°, combined with internal rotation

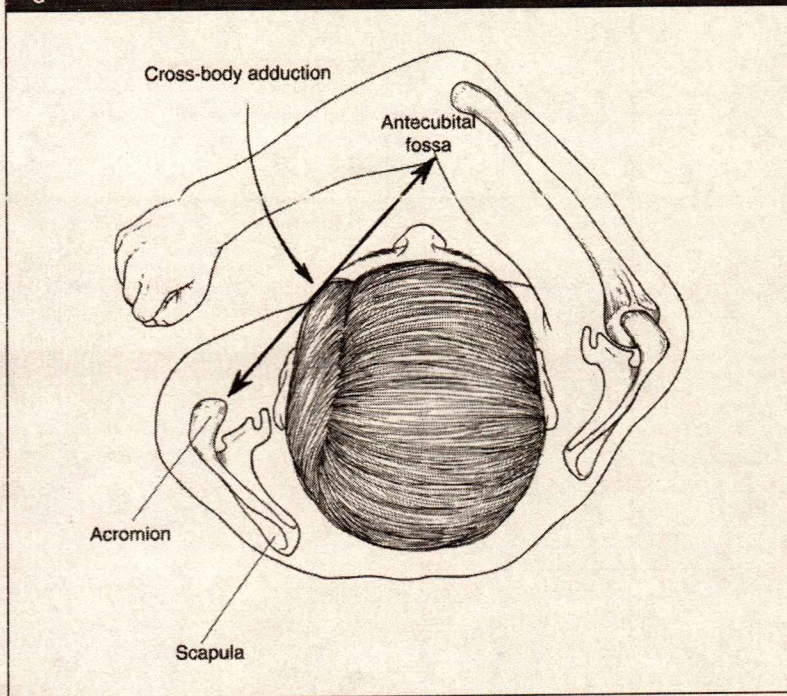
shift: dialysis -
Supine: canche
Tearing: dichinure -

and horizontal adduction, produces pain.¹ The physician must rule out acromioclavicular pathology, which also may cause pain during horizontal shoulder adduction. However, the patient with posterior capsular tightness also would be expected to test positive for the Hawkins impingement sign because the internal rotation stretches the posterior capsule. With impingement, subjective pain may be located anteriorly or anterolaterally, whereas with posterior capsular tightness, the pain is often posterior and reproduced with rotations that stretch the posterior capsule. In addition, the patient with posteroinferior capsule contracture reports a sense of posterior tightness.¹⁵

The arthroscopic impingement test may be observed from the lateral portal while flexing the shoulder anterior to the scapular plane through an arc of motion of 140° and observing the relationship of the humeral head to the acromion.²⁶ In the normal shoulder, the rotator cuff passes under the acromion, and the interval between the acromion and rotator cuff is maintained in all positions. Patients diagnosed with posterior capsular contracture were observed to have superior translation of the humeral head during flexion, with the rotator cuff contacting the undersurface of the acromion, thereby diminishing the subacromial space.⁸ However, after posterior capsule release, the kinematics of the shoulder can be restored and the subacromial space maintained.⁸

Several authors recommend screening the overhead throwing athlete for posteroinferior capsular contracture at the beginning of and during each season.^{16,23} This is because posteroinferior capsule contracture is the primary condition that initiates the pathologic cascade to a SLAP lesion and the subsequent development of dead arm syndrome.^{16,23} As long as the GIRD is less than or equal to its external rotation gain, the healthy throwing

Figure 7



Maximal cross-body adduction is the minimal distance from the antecubital fossa to the contralateral acromion when the arm is adducted horizontally across the body. (Adapted with permission from Matsen FA III, Lippitt SB, Sidles JA, Harryman DT II: *Practical Evaluation and Management of the Shoulder*. Philadelphia, PA: WB Saunders, 1994, p 21.)

shoulder has normal rotational kinematics without any form of glenohumeral instability throughout the throwing cycle.²³ However, when the GIRD exceeds the external rotation gain (ERG) (GIRD:ERG ratio >1), the shoulder may be at risk because of posterolateral shift of the glenohumeral rotation point with abduction and external rotation during the late cocking phase.²³ The risk of structural injury is directly proportional to the increase in the GIRD:ERG ratio.²³

Nonsurgical Management

In the absence of weakness or a prior surgical procedure, nonsurgical management is usually successful for the patient with posterior capsular

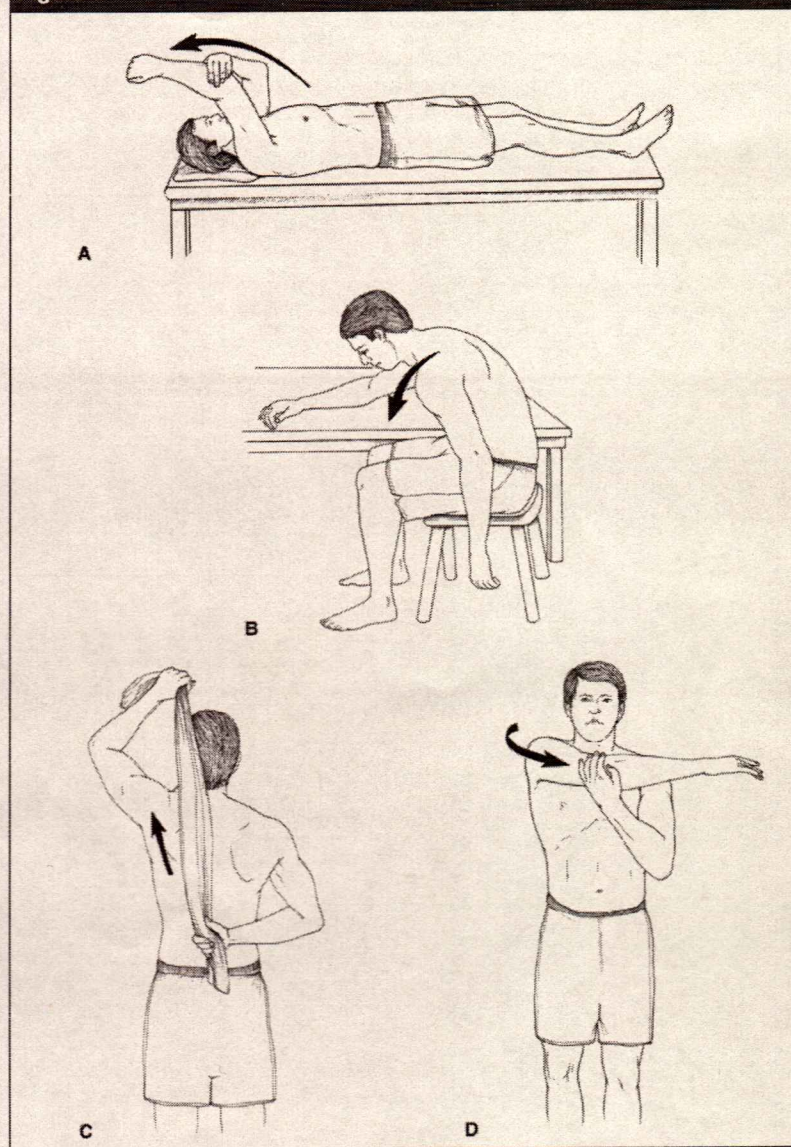
tightness.² Physician- or therapist-supervised patient-directed posterior capsular stretching is effective.² The patient performs gentle stretches five times per day² (Figure 8). Each stretch is performed until the patient feels a pull against the shoulder tightness, but not to the point of pain.² Each stretch is performed for 1 minute; thus, the patient invests approximately 30 minutes per day stretching.² Obvious improvement commonly occurs within the first month, but 3 months may be required to completely eliminate the condition.² Patients with chronic painful loss of internal rotation that is unresponsive to nonsurgical treatment may be candidates for arthroscopic capsular release.

The healthy throwing shoulder has normal rotational kinematics;

Gentle - down

*Translation supérieure de la tête humérale bas de la F avec diminution de l'espace m acromiale.
Screening: dépistage
La Décalage postéro-supérieur du point de rotation GH.
Weakness: faiblesse.*

Figure 8



Patient-directed posterior capsular stretching. **A**, Stretching in overhead reach using the opposite arm as the therapist. **B**, Stretching in overhead reach using the progressive forward lean to apply a gentle elevating force to the arm. **C**, Stretching in internal rotation using a towel to apply a gentle stretching force. **D**, Stretching in cross-body reach using the opposite arm as the therapist. (Adapted with permission from Matsen FA III, Lippitt SB, Sidles JA, Harryman DT II: *Practical Evaluation and Management of the Shoulder*. Philadelphia, PA: WB Saunders, 1994, pp 46-49.)

however, when the GIRD exceeds the ERG, the shoulder becomes vulnerable to further injury.¹⁶ Approximately 90% of all throwing athletes

with posteroinferior capsule contracture and symptomatic loss of internal rotation respond to a posteroinferior capsule stretching program.¹⁶

These athletes may be treated with sleeper stretches.^{16,23} The athlete lies on one side with the shoulder in 90° of flexion and the elbow in 90° of flexion.²³ The shoulder is passively internally rotated by pushing the forearm toward the table around a fixed elbow, which acts as the pivot point²³ (Figure 9). The loss of internal rotation usually can be improved to an acceptable level over 2 weeks with a compliant posteroinferior capsule stretching program using sleeper stretches.¹⁶

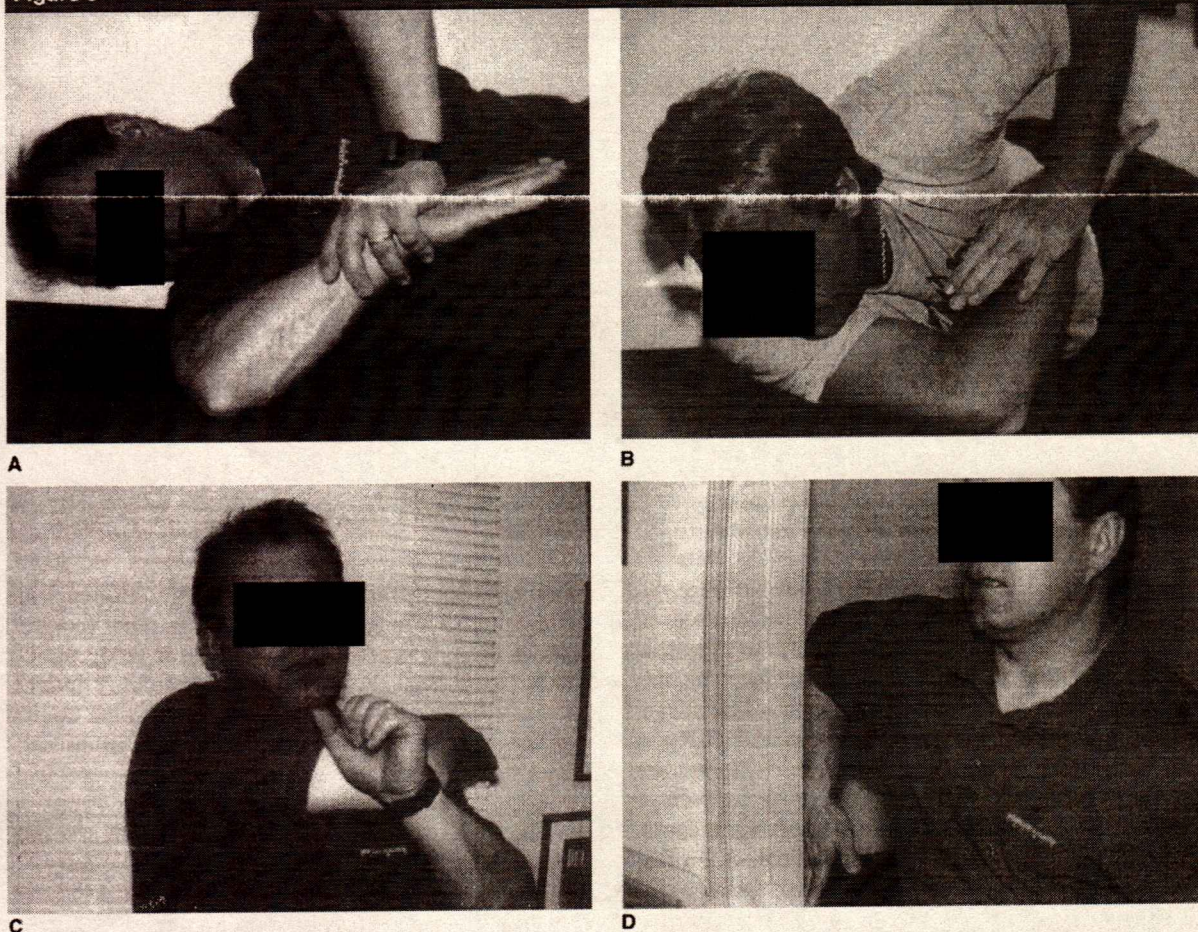
Ten percent of throwers do not respond to stretching; these patients tend to be older elite pitchers who have been throwing for years and have chronic long-standing symptoms.¹⁶ It is extremely unusual for high school and college pitchers to be nonresponsive to stretching; rarely have these younger pitchers needed selective posteroinferior capsulotomy.¹⁶ Baseball pitchers and other throwing athletes who have been stretch nonresponders may be considered for arthroscopic release of the posteroinferior capsule.²³

Surgical Management

Arthroscopic Posterior Capsule Release

General anesthesia, an interscalene block, or an interscalene catheter may be used with arthroscopic posterior capsule release.^{27,28} Warner et al^{24,29} and Ticker et al⁸ advocate regional anesthesia to improve postoperative control of pain, thereby allowing intensive physical therapy in the immediate postoperative period. An interscalene block using 30 mL of 0.5% bupivacaine with a 1:200,000 concentration of epinephrine provides adequate intraoperative anesthesia and, frequently, >6 hours of postoperative analgesia.^{24,29} Patients with an interscalene block can have repeat interscalene blocks in the morning of postoperative days 1 and 2, thereby allowing the patient and physical therapist to perform morning and afternoon ses-

Figure 9



Focused posterior inferior capsular stretches. **A**, In the sleeper stretch, the patient is side lying with the scapula stabilized against a wall, the shoulder flexed 90°, and the elbow flexed 90°. Passive internal rotation to the arm is applied by the nondominant arm to the dominant wrist. **B**, The roll-over sleeper stretch is the same as the sleeper stretch, except that the shoulder is flexed only 50° to 60° and the patient rolls forward 30° to 40° from vertical side lying. **C**, For the cross-arm stretch, the patient stands with the shoulder flexed 90°; passive adduction is applied by the uninvolved arm to the involved elbow. This primarily stretches the posterior musculature to a greater degree than the posterior inferior capsule. **D**, In the doorway stretch, the shoulder is abducted 90° and internally rotated. The elbow is flexed 90° with the elbow on the edge of an open doorway. The patient leans forward and inferior to apply an inferior capsular stretch to the shoulder. (Reproduced with permission from Burkhart SS, Morgan CD, Kibler WB: The disabled throwing shoulder: Spectrum of pathology. I: Pathoanatomy and biomechanics. *Arthroscopy* 2003;19:404-420.)

sions of passive ROM, in addition to the self-assisted exercises done by the patient.^{24,29}

To achieve regional anesthesia and postoperative analgesia through an interscalene catheter, a continuous infusion of 0.25% bupivacaine at a rate of 6 mL per hour can be administered for 48 hours postopera-

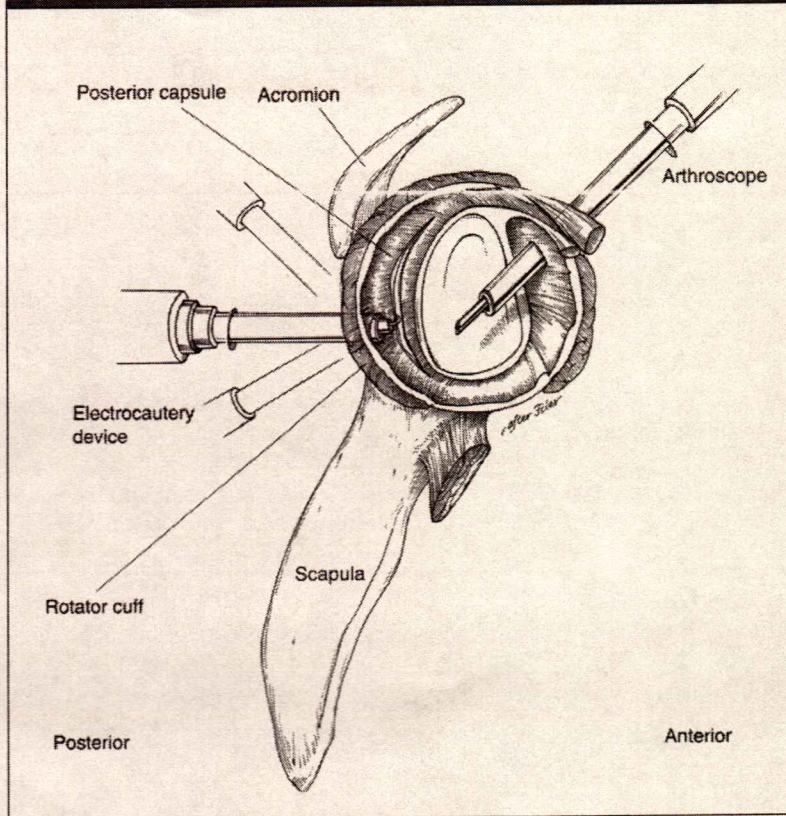
tively.^{24,27,29} Patients also may self-administer analgesia through an intravenous pump.^{24,29}

Warner et al²⁴ developed a technique for posterior capsule release for isolated loss of internal rotation. After diagnostic arthroscopy with the patient in the beach chair position, the arthroscope is placed in the

anterosuperior portal to visualize the posterior portion of the glenohumeral joint.²⁴ The posterior part of the capsule has been found to be thickened and shortened in all patients with posterior capsular contracture.^{8,24} An electrocautery device is then placed through the posterior portal cannula.²⁴ The capsule is di-

thickened: equiv.

Figure 10



Arthroscopic posterior capsule release in a right shoulder with the humeral head removed. The posterior capsule is released along the glenoid rim, and the electrocautery device is introduced through the posterior portal. The arthroscope is introduced through the anterior-superior portal. (Adapted with permission from Ticker JB, Beim GM, Warner JJP: Recognition and treatment of refractory posterior capsular contracture of the shoulder. *Arthroscopy* 2000;16:27-34.)

vided beginning just posterior to the biceps tendon origin on the superior glenoid rim at approximately the 11 o'clock position and continuing inferiorly to approximately the 8 o'clock position²⁴ (Figure 10). The posterior capsule is divided adjacent to the glenoid rim because the rotator cuff muscles at this level are superficial to the capsule.²⁴ If there were additional lateral division of the capsule, the tendons of the rotator cuff would be at risk for injury because they are conjoined with the capsule.^{11,30} The depth of the capsular division is complete when the muscle fibers of the rotator cuff are visible.²⁴

An arthroscopic shaver is then inserted to remove the ragged edges of the capsule in order to clearly identify the capsular edge and rotator cuff muscle.⁸ A shaver creates a wider gap in the resected capsule to help avoid recurrence.⁸ Extending the release into the inferior aspect of the axillary pouch exposes the axillary nerve to injury by either thermal or electrical energy.³¹

After removing the arthroscope, gentle manipulation completes the release of any remaining capsular fibers to restore internal rotation and flexion.²⁴ Motion usually is improved through a gradual yielding of

tissue, similar to stretching a rubber band, rather than by the discrete improvement of motion seen after anterior capsule release.²⁴

Arthroscopic Selective Posteroinferior Capsulotomy

When the posteroinferior aspect of the capsule is tight, as may occur in the overhead throwing athlete, a selective posteroinferior capsulotomy may be performed. The capsular contracture is located in the posteroinferior quadrant of the capsule in the zone of the posterior band of the IGHL complex.¹⁶ The capsulotomy is made 0.25 inches away from the labrum from the 9 o'clock position to the 6 o'clock position.¹⁶ Typical arthroscopy findings in these patients include a severely contracted and thickened posteroinferior recess in the zone of the posterior band of the IGHL complex.¹⁶ In most patients, the capsule in this zone is ≥ 6 mm thick.¹⁶ After selective posteroinferior capsulotomy, the patient can expect an immediate 65° increase in glenohumeral internal rotation.¹⁶

Postoperative Management

Warner et al^{24,29} recommend passive motion with both morning and afternoon sessions on the first postoperative day. In addition, the physical therapist should instruct the patient in self-assisted motion exercises. Patients were discharged after the afternoon session on the second postoperative day.^{24,29} For the first 2 weeks, the authors recommend daily supervised therapy 5 days per week in addition to a home-exercise program consisting of pulley and cane-assisted motion in all planes. For the next 4 weeks, the patient should attend supervised therapy three times per week.^{24,29} The home exercise program can be advanced during this time.⁸ After 6 weeks, the rehabilitation may be individualized according

Attempt: tentative.

Pas d'instabilité postérieure observée.

Undergones: arthro

to the patient's progress.^{8,24,29}

Warner et al^{24,29} recommend against using a sling for support at any time, and they encourage the patient to use the operated arm for activities of daily living as soon as possible after surgery. Strengthening is begun as soon as postoperative pain and active shoulder motion allow.^{24,29} Patients are encouraged to attempt to swim in a pool between 2 and 4 weeks after the operation.^{24,29}

In our experience, posterior capsule contracture release may be performed as an outpatient procedure with good results. Close follow-up is necessary to ensure patient compliance with shoulder-stretching and ROM exercises. The physical therapy program, including stretching and ROM, should be familiar to these patients because they would have had physical therapy before considering surgery (Figure 8).

In the throwing athlete, the gain in internal rotation must be maintained by an immediate postoperative internal rotation stretching program in order to prevent the capsulotomy gap from closing during healing.¹⁶ Sleeper stretches are performed beginning postoperative day 1.³²

Postoperative Results

Warner et al²⁴ reported good results with arthroscopic posterior capsule release for isolated loss of internal rotation in five patients. The function of all shoulders was graded according to the 100-point Constant and Murley scoring system.³³ The Constant and Murley score improved a mean of 20 points (range, 5 to 35).²⁴ Mean improvement in internal rotation in abduction was 42° (range, 30° to 60°; $P < 0.005$); with the arm in adduction, mean improvement in internal rotation was four spinous-process levels (range, 1 to 10 levels; $P < 0.05$).²⁴

Ticker et al⁸ reported on arthroscopic posterior capsule release in nine patients, with average postoperative follow-up of 19 months (range,

11 to 35 months). There were no postoperative complications, and posterior instability was not observed postoperatively. The average preoperative internal rotation in abduction was 10° (range, -10° to 40°) for the involved side compared with 58° (range, 50° to 80°) for the contralateral side.⁸ Postoperative internal rotation in abduction increased by an average of 37° (range, 30° to 50°) to an average motion of 47° (range, 30° to 80°), which was statistically significant ($P < 0.01$).⁸ In forward flexion, the average preoperative motion for the involved shoulder was 133° (range, 95° to 150°) and for the noninvolved shoulder, 156° (range, 150° to 170°).⁸ Forward flexion improved an average of 15° (range, -20° to 45°) to an average motion of 148° (range, 130° to 160°).⁸ Although there was a trend toward gains in forward flexion, they were not statistically significant compared with preoperative values.⁸

Discussion

Posterior capsular contracture is typically a painful condition associated with loss of internal rotation and horizontal adduction. In addition, forward flexion may be reduced because of altered glenohumeral kinematics. This occurs because a shortened posterior capsule may result in anterosuperior translation of the humeral head during flexion, with subsequent nonoutlet impingement.⁹ Ticker et al⁸ noted the presence of subacromial bursitis in all cases, lending further support for this non-outlet form of impingement. Their treatment included removing inflamed bursal tissue without an acromioplasty. Normal ROM of the shoulder without objective physical evidence and normal strength is usually consistent with a diagnosis of impingement syndrome. Pain caused by posterior capsular tightness is not a result of direct pathology of the coracoacromial arch. However, im-

pingement may occur because of dynamic translation of the humeral head anteriorly and superiorly.⁷

Loss of motion after posterior capsular shift for instability is a rare occurrence.³⁴⁻³⁷ Ticker et al⁸ reported that some of their patients with isolated refractory posterior capsule contracture had undergone a prior posterior capsule shift procedure. All of the other patients reported a specific event that they described as a traction injury to the affected arm. Surgical procedures performed to manage a variety of conditions, including classic impingement, may be a factor in posterior capsular contracture. In the series of Ticker et al,⁸ five of nine patients (56%) had undergone prior procedures; in all of these cases, the prior surgical approaches had failed.

All patients in the series of Warner et al²⁴ and Ticker et al⁸ had a contracted and thickened posterior capsule at the time of arthroscopy. According to Burkhart et al,¹⁶ in most cases, the capsule in this zone is ≥ 6 mm thick. It is unclear why the posterior capsule undergoes this process, whereas the anterior capsule is spared. Matsen et al² reported that this condition is a common result of injury to the rotator cuff. Ticker et al⁸ postulated that, in the cases of injury associated with a traction mechanism, trauma to the posterior capsule may result in localized and excessive scarring. In patients who underwent a posterior capsular shift procedure, either the posterior capsule was overtightened or there was excessive scarring with subsequent collagen shortening in this region after the repair.

Several cases have been reported of successful open posterior capsule release performed after posterior capsular shift.³⁸ However, an open posterior capsule release may produce injury to the rotator cuff, thereby impeding rehabilitation. Warner et al²⁴ determined that an arthroscopic procedure can release as much capsule as an open release; other authors⁸ report that arthroscopic posterior cap-

sule release with subacromial bursectomy is a reliable management option with minimal morbidity.

Pain control after closed manipulation for adhesive capsulitis is critical.^{10,13,39} Similarly, Warner et al²⁹ report that postoperative analgesia is an essential part of the rehabilitation program after arthroscopic release of posterior capsule contracture. Interscalene anesthesia is reportedly safe and well tolerated. It significantly reduces the need for narcotics while allowing aggressive passive ROM in the immediate postoperative period.^{10,27,28,39}

Summary

In patients with suspected shoulder impingement, careful examination of passive and active motion in all planes is necessary to diagnose posterior capsule contracture. In patients with limited internal rotation with or without limited flexion, a therapy program directed at improving motion in the deficient planes should be instituted. When nonsurgical management fails and painful limitation of motion persists, arthroscopic posterior capsule release with subacromial bursectomy is a reliable treatment with minimal morbidity. Postoperative physical therapy is imperative for both maintaining motion that has been gained intraoperatively and providing maximum shoulder function.

In the overhead throwing athlete, several authors recommend screening for posteroinferior capsular contracture at the beginning of and during each season because it can initiate a pathologic cascade to a SLAP lesion and, subsequently, to dead arm syndrome. The healthy throwing shoulder has normal rotational kinematics without any form of glenohumeral instability throughout the throwing cycle as long as its GIRD is less than or equal to its ERG. However, when the GIRD exceeds the ERG, the shoulder becomes vulnerable for risk of struc-

tural injury directly proportional to the increase in the GIRD:ERG ratio. When sleeper stretches fail to treat the GIRD to an acceptable level, stretch nonresponders may be considered for arthroscopic posteroinferior capsulotomy.

References

Evidence-based Medicine: Levels III and IV case series are reported but no prospective randomized series.

Citation numbers printed in **bold type** indicate references published within the past 5 years.

1. Hawkins RJ, Hobeika PE: Impingement syndrome in the athletic shoulder. *Clin Sports Med* 1983;2:391-405.
2. Matsen FA III, Arntz CT, Lippitt SB: Rotator Cuff, in Rockwood CA, Matsen FA III (eds): *The Shoulder*, ed 2. Philadelphia, PA: WB Saunders, 1998, vol 2, pp 755-839.
3. Neer CS II: Impingement lesions. *Clin Orthop Relat Res* 1983;173:70-74.
4. Neviasser RJ: Painful conditions affecting the shoulder. *Clin Orthop Relat Res* 1983;173:63-69.
5. Neer CS II: Anterior acromioplasty for the chronic impingement syndrome in the shoulder: A preliminary report. *J Bone Joint Surg Am* 1972;54:41-50.
6. Tyler TE, Nicholas SJ, Roy T, Gleim GW: Quantification of posterior capsule tightness and motion loss in patients with shoulder impingement. *Am J Sports Med* 2000;28:668-673.
7. Harryman DT II, Sidles JA, Clark JM, McQuade KJ, Gibb TD, Matsen FA III: Translation of the humeral head on the glenoid with passive glenohumeral motion. *J Bone Joint Surg Am* 1990;72:1334-1343.
8. Ticker JB, Beim GM, Warner JJP: Recognition and treatment of refractory posterior capsular contracture of the shoulder. *Arthroscopy* 2000;16:27-34.
9. Neer CS II: Frozen shoulder, in Neer CS II (ed): *Shoulder Reconstruction*. Philadelphia, PA: WB Saunders, 1990, pp 422-427.
10. Harryman DT II: Shoulders: Frozen and stiff. *Instr Course Lect* 1993;42:247-257.
11. Kieras DM, Matsen FA III: Open release in management of refractory frozen shoulder. *Orthop Trans* 1991;15:801-802.
12. Lusardi DA, Wirth MA, Wurtz D, Rockwood CA Jr: Loss of external rotation following anterior capsulorrhaphy of the shoulder. *J Bone Joint Surg Am* 1993;75:1185-1192.
13. Neviasser RJ, Neviasser TJ: The frozen shoulder: Diagnosis and management. *Clin Orthop Relat Res* 1987;223:59-64.
14. Ogilvie-Harris DJ, Biggs DJ, Fitsialos DP, MacKay M: The resistant frozen shoulder: Manipulation versus arthroscopic release. *Clin Orthop Relat Res* 1995;319:238-248.
15. Burkhart SS, Morgan CD, Kibler WB: Shoulder injuries in overhead athletes: The "dead arm" revisited. *Clin Sports Med* 2000;19:125-158.
16. Burkhart SS, Morgan CD, Kibler WB: The disabled throwing shoulder: Spectrum of pathology. I: Pathoanatomy and biomechanics. *Arthroscopy* 2003;19:404-420.
17. Levitz CL, Dugas J, Andrews JR: The use of arthroscopic thermal capsulorrhaphy to treat internal impingement in baseball players. *Arthroscopy* 2001;17:573-577.
18. Cooper DE, O'Brien SJ, Warren RF: Supporting layers of the glenohumeral joint: An anatomic study. *Clin Orthop Relat Res* 1993;289:144-155.
19. Gerber A, Apreleva M, Warner JJP: Basic science of glenohumeral instability, in Norris TR (ed): *Orthopaedic Knowledge Update: Shoulder and Elbow 2*. Rosemont, IL: American Academy of Orthopaedic Surgeons, 2002, pp 13-22.
20. O'Brien SJ, Neves MC, Arnoczky SP, et al: The anatomy and histology of the inferior glenohumeral ligament complex of the shoulder. *Am J Sports Med* 1990;18:449-456.
21. Gerber C, Werner CM, Macy JC, Jacob HA, Nyffeler RW: Effect of selective capsulorrhaphy on the passive range of motion of the glenohumeral joint. *J Bone Joint Surg Am* 2003;85:48-55.
22. Burkhart SS, Morgan CD: The peel-back mechanism: Its role in producing and extending posterior type II SLAP lesions and its effect on SLAP repair rehabilitation. *Arthroscopy* 1998;14:637-640.
23. Burkhart SS, Morgan CD, Kibler WB: The disabled throwing shoulder: Spectrum of pathology. III: The SICK scapula, scapular dyskinesis, the kinetic chain, and rehabilitation. *Arthroscopy* 2003;19:641-661.
24. Warner JJ, Allen AA, Marks PH, Wong P: Arthroscopic release of postoperative capsular contracture of the shoulder. *J Bone Joint Surg Am* 1997;79:1151-1158.

Spntf armé/lancer → Dépasse de la raideur de la Capsule postéro-inférieure.

25. Matsen FA III, Lippitt SB, Sidles JA, Harryman DT II: Shoulder motion, in Matsen FA III, Lippitt SB, Sidles JA, Harryman DT II (eds): *Practical Evaluation and Management of the Shoulder*. Philadelphia, PA: WB Saunders, 1994, pp 19-58.
26. Warner JJ, Kann S, Maddox LM: The "arthroscopic impingement test." *Arthroscopy* 1994;10:224-230.
27. Brown AR, Weiss R, Greenberg C, Flatow EL, Bigliani LU: Interscalene block for shoulder arthroscopy: Comparison with general anesthesia. *Arthroscopy* 1993;9:295-300.
28. Kinnard P, Truchon R, St-Pierre A, Montreuil J: Interscalene block for pain relief after shoulder surgery: A prospective randomized study. *Clin Orthop Relat Res* 1994;304:22-24.
29. Warner JJ, Allen A, Marks PH, Wong P: Arthroscopic release for chronic, refractory adhesive capsulitis of the shoulder. *J Bone Joint Surg Am* 1996; 78:1808-1816.
30. Clark J, Sidles JA, Matsen FA: The relationship of the glenohumeral joint capsule to the rotator cuff. *Clin Orthop Relat Res* 1990;254:29-34.
31. Zanotti RM, Kuhn JE: Arthroscopic capsular release for the stiff shoulder: Description of technique and anatomic considerations. *Am J Sports Med* 1997;25:294-298.
32. Burkhart SS, Morgan CD, Kibler WB: The disabled throwing shoulder: Spectrum of pathology. II: Evaluation and treatment of SLAP lesions in throwers. *Arthroscopy* 2003;19:531-539.
33. Constant CR, Murley AH: A clinical method of functional assessment of the shoulder. *Clin Orthop Relat Res* 1987;214:160-164.
34. Fronek J, Warren RF, Bowen M: Posterior subluxation of the glenohumeral joint. *J Bone Joint Surg Am* 1989;71: 205-215.
35. Gerber C, Ganz R, Vinh TS: Glenoplasty for recurrent posterior shoulder instability: An anatomic reappraisal. *Clin Orthop Relat Res* 1987;216:70-79.
36. Hawkins RJ, Koppert G, Johnston G: Recurrent posterior instability (subluxation) of the shoulder. *J Bone Joint Surg Am* 1984;66:169-174.
37. Mowery CA, Garfin SR, Booth RE, Rothman RH: Recurrent, posterior dislocation of the shoulder: Treatment using a bone block. *J Bone Joint Surg Am* 1985;67:777-781.
38. Warner JJ, Iannotti JP: Treatment of a stiff shoulder after posterior capsulorrhaphy: A report of three cases. *J Bone Joint Surg Am* 1996;78:1419-1421.
39. Pollock RG, Duralde XA, Flatow EL, Bigliani LU: The use of arthroscopy in the treatment of resistant frozen shoulder. *Clin Orthop Relat Res* 1994;304:30-36.